



**PATIENT**

Stevie Lowen

**SPECIES**

Feline

**BREED**

Sphynx

**SEX**

Female Spayed

**AGE**

7 years

**WEIGHT**

10.6lbs

**INTERPRETED BY**

Maggie Machen Lamy,  
DVM, DACVIM  
(Cardiology)

**IMAGING PERFORMED BY**

Iacovides, DVM

**HOSPITAL NAME**

Tuxedo Animal  
Hospital

**REFERRING VET**

Dr. Broughton

**INVOICE**

47411

**DATE**

4/9/26

**PRESENTING CLINICAL SIGNS**

History: Recheck echo. On Rapamycin.  
-Pertinent previous echo findings (10/2025 MML): NSF – history of HOCM.

**ECHOCARDIOGRAM FINDINGS**

2D, m-mode, color flow and doppler imaging is available. The left ventricular wall is normal in dimension. There is a mildly hyperechoic endocardium consistent with mild fibrosis. The endocardium also appears mildly remodeled. The papillary muscles are normal in size and hyperechoic. The left atrium is normal in size. The right atrium is normal in size. The right ventricle appears normal. The mitral valve is normal in structure and mobility. No obvious valve regurgitation. Blood flow through both the LVOT and RVOT is normal in velocity. No pleural or pericardial effusion seen. No obvious cardiac tumors.

**CARDIAC CHART**

FELINE CARDIAC PARAMETERS	BODY WEIGHT (kg)	HR (BPM)	IVSd (cm) <small>(Moise, Pipers)</small>	LVIDd (cm) <small>(Moise, Pipers)</small>	LVWd (cm) <small>(Moise, Pipers)</small>	FS (%)	EF (%)
<b>NORMAL PARAMETER</b>	-----	150-240	0.35-0.55	<2 (mean 1.5)	3.5-0.55	35-67	80-100
<b>PATIENT</b>	4.8	NM	0.50	1.4	0.50	45	86
FELINE CARDIAC PARAMETERS	LA/AO <small>(Boon)</small>	LA/AO HEART BASE <small>(Swe) (Abbott)</small>	LA 2D short axis Base view (cm) <small>(Abbott)</small>		LVOT VEL  (m/s)	RVOT VEL  (m/s)	E max  (m/s)
<b>NORMAL</b>	<1.5	<1.3	<1.2		<1.6	<1.3	<0.9
<b>PATIENT</b>	NM	1.3	1.2		1.3	1.3	NM

*\*Note: All measurements based upon multi-modal images and methods. An average value is reported.  
Adapted from June Boon, Veterinary Echocardiography, 1998  
Abbott J & MacLean H JVIM 2006;20: 111-119, Moise et al. Am J Vet Res 47:1476, 1986. Pipers et al. Am J Vet Res 40:882, 1979.*

**INTERPRETATION OF THE FINDINGS & FURTHER RECOMMENDATIONS**

Persistently normal findings. No LV hypertrophy is seen, which is good news, The LA is normal and no pathology is identified.

Given these findings, it is reasonable to continue Rapamycin, although long-term benefit is unknown. Prognosis is good.

Anesthetic risk is considered mild. Risk for complication with steroid use or fluid administration typically follows LA dilation, which in this case is low. That being said, any cat can experience unexpected signs of intolerance and monitoring of RR/RE is advised particularly in the initiation phase.

Recommend recheck echocardiogram in 1 year to assess for any progressive issues.



## PATIENT

Stevie Lowen

## SPECIES

Feline

## BREED

Sphynx

## SEX

Female Spayed

## AGE

7 years

## WEIGHT

10.6lbs

## INTERPRETED BY

Maggie Machen Lamy,  
DVM, DACVIM  
(Cardiology)

## IMAGING PERFORMED BY

Iacovides, DVM

## HOSPITAL NAME

Tuxedo Animal  
Hospital

## REFERRING VET

Dr. Broughton

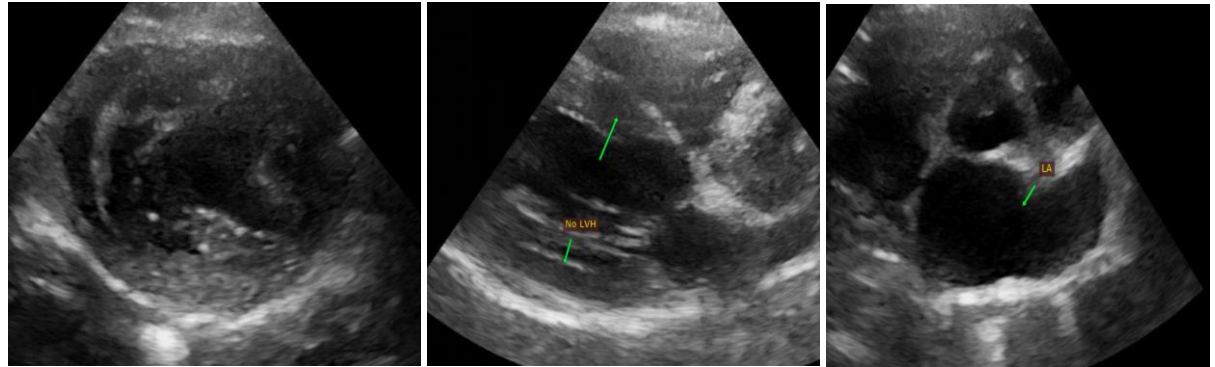
## INVOICE

47411

## DATE

4/9/26

## IMAGES



The information and recommendations provided are based on the images presented by the referring veterinarian. No evaluation can be communicated regarding pathology that was not visible in the image/video clips provided.

Thank you for this referral. This report was generated using transcription software, and minor dictation errors may be present. If the clinical or image interpretation does not parallel your findings or if I can be of any further assistance, please contact me.

**Maggie Machen Lamy, DVM**

**Diplomate of the American College of Veterinary Internal Medicine (Cardiology)**

info@sonopath.com